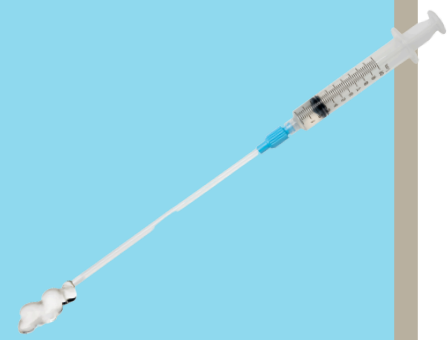



## CASE REPORT

### Hysteroscopic Metroplasty and Myomectomy

#### Case Introduction



**Dr. Marcia Penteado**

São Paulo, Brazil

- Hysteroscopy Specialist at Perola Byington Hospital and Women's Hospital
- Member of the Hysteroscopy Committee of the SBE (Brazilian Society of Endometriosis)

Additional Authors:

Ana Paula Carvalho Moura, Pedro Gonzalez do Valle, Mariana Araujo Cortes Silva, Catharina Braga Ferreira dos Santos

A 32-year-old patient from Sao Paulo was referred to the Women's Hospital-SP due to recurrent miscarriages, secondary infertility, and a magnetic resonance imaging diagnosis of a septate uterus. The diagnostic hysteroscopy showed two hemi cavities separated by an incomplete septum and a submucous myoma (G2-Lasmar 1).

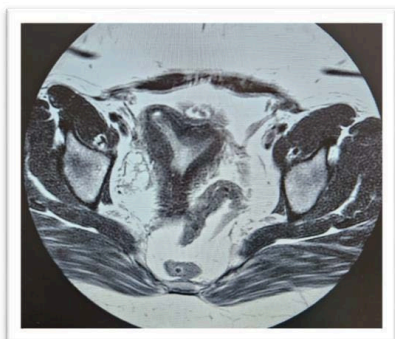
The patient underwent surgical hysteroscopy for myomectomy by enucleation and metroplasty. The procedure was guided by a transabdominal ultrasound, achieving a complete opening of the uterine cavity, followed by the application of intrauterine gel for the prevention of adhesions.

In the hysteroscopy, performed 30 days after the procedure, no intrauterine adhesions were visualized. The patient was referred for follow-up with an assisted reproduction team for in vitro fertilization treatment. This case report is a continuation of a series of 3 cases, in which metroplasties associated with the application of gel were performed, with the objective of evaluating the prevention of intrauterine adhesions following complex surgical hysteroscopies(1).

#### Case Presentation

The patient was referred to the Women's Hospital-SP due to obstetric history of recurrent miscarriages, five previous uterine curettages, and secondary infertility. The patient had pelvic magnetic resonance imaging on 10/9/2021, showing a bicornuate uterus, uterine myomatosis and thickening of the uterosacral ligaments, suggesting endometriosis. A new magnetic resonance imaging, performed on 12/02/2022, showed a septate uterus, with a septum extending from the uterine fundus to the isthmus, measuring approximately 2cm thick. Signs of adenomyosis were also observed (Photo 1).

**Photo 1**



## Hysteroscopic Metroplasty and Myomectomy

## CASE REPORT

### Operative Approach

Given the suspicion of uterine malformation by the magnetic resonance imaging examination, the investigation continued with a diagnostic hysteroscopy.

The procedure was performed on 5/10/23 by vaginoscopy technique, in a day hospital. This was done without anesthesia and with the Bettocchi system, with a 2.9mm 30-degree optic and 0.9% saline as a distension medium. The examination showed a vaginal canal without alterations, a single uterine cervix, a normal cervical canal, and the presence of two hemi endometrial cavities separated by an incomplete septum that extended from the uterine fundus to the middle third of the uterine cavity. It also showed the presence of a submucous myoma in the anterior wall of the isthmic region, measuring about 2cm (G2-Lasmar 1) (Photo 2).

The patient underwent surgical hysteroscopy on 08/25/2023 using a monopolar resectoscope, 4mm 30° optic, Collins electrode, glycine as a distension medium, under spinal anesthesia. The evaluation of the uterine cavity described as per previous diagnostic hysteroscopy was confirmed. Enucleation of the submucous myoma and metroplasty were performed, guided by transabdominal ultrasound, showing a complete opening of the uterine cavity (Photo 3).

After re-establishing the anatomy of the uterine cavity, 10 mL of absorbable and anti-adherent intrauterine gel was inserted into the uterus. The dual polymer gel was developed by FzioMed and marketed in Brazil by LAS Brasil, composed of carboxymethylcellulose (CMC) and polyethylene oxide (PEO), known as Oxiplex/IU® (FzioMed, San Luis Obispo, CA, USA), with the aim of preventing intrauterine adhesions. (Photo 4)

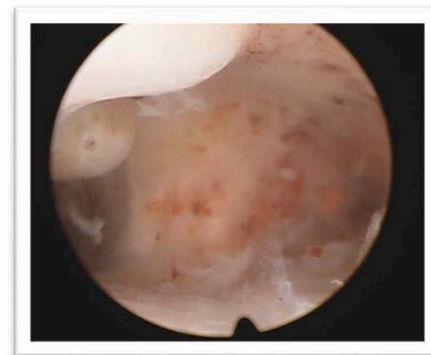

Photo 2

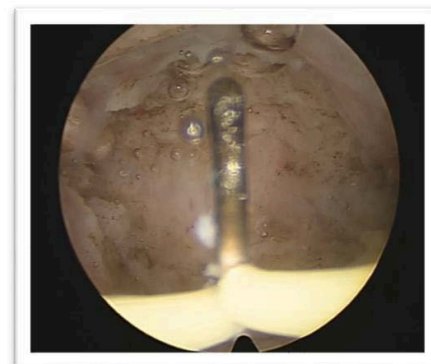


Photo 3

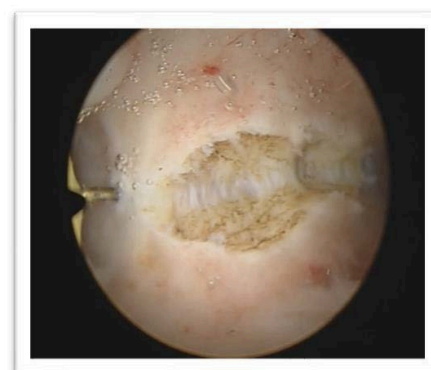

Photo 4

## Hysteroscopic Metroplasty and Myomectomy

## CASE REPORT

### Post Procedure

In the postoperative follow-up, the patient underwent control magnetic resonance imaging on 09/07/2023 which showed an anteverted uterus, normal dimensions, regular contours, and preserved signal intensity; signs of adenomyosis; without other relevant changes (Photo 5).

A follow up hysteroscopy was performed 30 days after the procedure, on 09/29/2024, where a triangular, normal-sized uterine cavity, secretory endometrium, bilateral tubal ostia visualized, and normal uterine fundus were seen.

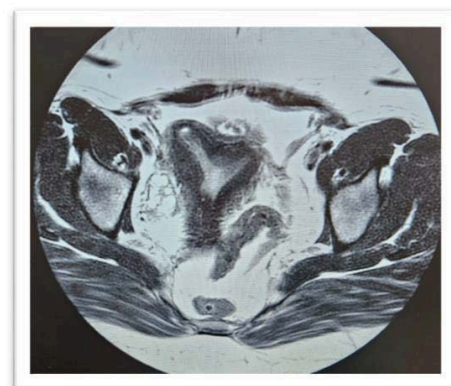


Photo 5

### Conclusion

There were no intrauterine adhesions seen during the hysteroscopy performed 30 days after the procedure.

After the hysteroscopic removal of the intrauterine septum and uterine myoma, the patient was released for follow-up to the assisted reproductive team for in vitro fertilization (1).

### REFERENCES

1. da Cunha Viera M, Kondo W, Menakaya U and diZerega G, Difficult Hysteroscopic Surgery and Intrauterine Carboxymethyl Cellulose = Polyethylene Oxide Dual Polymer Gel Resulted in Good Clinical Outcomes: Three Case Reports. Journal of Clinical Obstetrics, Gynecology and Infertility